

INSTITUTO BARRAQUER DE AMERICA

Vol. 6 - Nos. 3-4

1968

ARCHIVOS  
DE LA  
SOCIEDAD AMERICANA  
DE  
OFTALMOLOGIA Y OPTOMETRIA

**10º. ANIVERSARIO**

**PARTE SEGUNDA**

**PRIMUM FORUM OPHTHALMOLOGICUM**

**Lunes 16 a Viernes 20 de Marzo de 1970**

**Apartado Aéreo 20945, Bogotá (2) Colombia**

ARCHIVOS DE LA SOCIEDAD  
AMERICANA DE OFTALMOLOGIA  
Y OPTOMETRIA

INSTITUTO BARRAQUER DE AMERICA

ARCHIVOS

DE LA

SOCIEDAD AMERICANA

DE

OFTALMOLOGIA Y OPTOMETRIA

---

---

Vol. 6

1968

Nos. 3-4

---

---

SECRETARIO GENERAL Y DE REDACCION:

**SALOMON REINOSO A., M. D.**

APARTADO NACIONAL 700/2

BOGOTA - COLOMBIA

SUMARIO - SUMMARY

	<i>Págs.</i>
EDITORIAL .....	301
DEREK AINSLIE, M.D. PENETRATING CORNEAL GRAFTS .....	303
JOSÉ QUERATOPLASTIA REFRACTIVA .. .....	309
E. D. BLAVAIKAYA, M. D. INTRALAMB OF REFRACTION OF THE EYE .. .....	311
H. W. HOFSTETTER, O.D. ABSOLUTE THRESHOLD MEASUREMENTS WITH THE DIASTEREO TEST ..	327
TADEUSZ KIWAWICZ, M.D. RECENT IMPROVEMENTS IN THE CRYOSURGERY OF CATARACT ..	343
HANS LIETMANN, Ph.D. NEW TELEOBJECTIVES FOR THE OPERATION MICROSCOPE AFTER BARRAQUER .. .....	349
ALY MORTADA, M.D. ECCENTRIC FIXATION CASES CURED BY PLEOPTICS ... .....	357
HÉCTOR NANO, M.D. - HUMBERTO PÉREZ, M.D. - DOMINGO R. ALBORNOZ, M. D. ATROFIA ESENCIAL DE IRIS Y Distrofia DE DOYNE .. .....	365
F. PAYRAG, M.D. - H. CHABAT-RIVIERE, M.D. TRAITEMENT DER KERATITES ULCI PUESES DAD LA LUMIERE A L'LAIDE D'UN PHOTOCOAGULATEUR .. .....	383
MAGDA RADNOT, M.D. - B. LOVAS. DATA ON THE ULTRASTRUCTURE OF MÜLLER'S CELLS OF THE RETINA .. .....	393

	<i>Págs.</i>
SIGMOND SUGS, M.D. ASPECTS PHYSIOLOGIQUES DE L'ADAPTATION REGIONALE A L'OBS- CURITE CHEZ LES NORMAUX Y COMPRIS LA SOMMATION SPATIALE	405
REVISION DE LITERATURA .....	445
ACTIVIDADES DE LA SOCIEDAD AMERICANA DE OFTALMOLOGIA Y OPTOMETRIA .....	447
SOCIEDAD AMERICANA DE OFTALMOLOGIA Y OPTOMETRIA: 1968 SCIENTIFIC PROGRAMME PROGRAMA CIENTIFICO PARA 1968 .....	449
NOTICIAS .....	453
INDICE DE MATERIAS Y AUTORES .....	455
INDEX .....	455

SOCIEDAD AMERICANA  
DE  
OFTALMOLOGIA Y OPTOMETRIA

JUNTA DIRECTIVA

Vicente Rodriguez P., M. D.

Hernando Henao R., O. D.

Salomón Reinoso A., M. D.

José I. Barraquer M., M. D.

Wesley Newton, O. D.

Francisco Barraquer C., M. D.

Carlos Téllez D., O. D.

SECRETARIO GENERAL Y DE  
REDACCION

Salomón Reinoso A., M. D.

TESORERO

Carlos Téllez D., O. D.

## EDITORIAL

La operación de Catarata, piedra de toque, del cirujano oftalmólogo, alcanzó hace años una gran perfección por su técnica depurada y constancia en sus resultados. A pesar de ello, año tras año, nuevas aportaciones, descubrimientos y la adopción de medidas complementarias, fueron simplificando su técnica, disminuyendo las complicaciones, acortando la convalecencia y mejorando los resultados.

En los últimos años, dos métodos, uno antiguo, rehabilitado por la buena anestesia y la introducción del microscopio quirúrgico, y otro nuevo, han vuelto obsoletos en la práctica de rutina los métodos tradicionales para la extracción del cristalino: La aspiración, con o sin facoemulsión, bajo control microscópico, para las cataratas de niños y jóvenes, y a la crio-extracción. La crio-extracción total está indicada.

Es natural que existan reticencias y hasta cierta oposición a nuevos métodos que requieren nuevos hábitos, nuevo instrumental y nuevos conceptos.

La micro-cirugía en la aspiración y la crio-extracción, son todavía procedimientos jóvenes y sufrirán muchos perfeccionamientos y simplificaciones, pero ya en la actualidad, a pesar de la duda, constituyen los métodos de elección en el tratamiento quirúrgico de la catarata.

El uso de bajas temperaturas en terapéutica durante el último patrimonio exclusivo de dermatología, se inició en cirugía ocular por Bietti, en 1932, para crear una coroiditis adhesiva en el tratamiento del desprendimiento de la retina, por J. L. Barraquer en 1953 para endurecer la córnea y permitir su talla óptica y en 1961 por Krwawitz para obtener una sólida presa en el cristalino. Posteriormente se extienden sus indicaciones al tratamiento del glaucoma, del herpes corneal, conjuntivitis primaveral, etc. No sabemos hasta dónde llegarán las posibilidades de la crio-oftalmología, pero por el momento, consideramos afortunados de haber asistido a su nacimiento, y deseamos que continúe desarrollándose y poder predecirle un brillante porvenir.

## PENETRATING CORNEAL GRAFTS

BY

DEREK AINSLIE, M. D.

London, England

In 1949 when I first developed an interest in keratoplasty, it was usual to secure penetrating corneal grafts by indirect fixation using crossover sutures.

At this time there was a large reserve of cases of corneal opacities due to past interstitial keratitis, and these provided much of the material for keratoplasty. Indeed, of the first hundred penetrating corneal grafts I performed, thirty-five were for interstitial keratitis.

Scarring due to this disease is one of the most favourable indications for corneal grafting. A small graft of only 5 millimetres is usually adequate and wound healing is very rapid. Thus conditions for success are almost ideal.

It became apparent, too, that the post-operative graft oedema which had so often spoiled the result in the earlier days of keratoplasty could be controlled by the newly available cortisone.

Nevertheless, even in the small grafts performed for interstitial keratitis, fixation by cross sutures was not always adequate unless the patient was very co-operative. For grafts of over five millimetres the method was much too unreliable.

Barraquer had already described edge to edge sutures for corneal graft fixation. (Barraquer Moner, J. L., 1943, 1949). Although this is now the method most frequently employed, initially the uncertainty in obtaining really fine needles and suture material made it difficult to apply universally. At the Ophthalmological Congress of the United Kingdom in 1952 Seymour Philips described a method of fixation using a solid plastic splint, in appearance like a corneal contact lens. (Philips, A. S. and Fincham, E. F., 1952).

The greatest disadvantage of the original splint method was a delay in healing of the wound, a serious matter since this splint could seldom be left in position for more than three weeks. Philips quickly observed that healing was slower than where cross sutures were used and considered that this was likely to be due to the exclusion of tears and air from the graft surface. To overcome this, he introduced the perforated "pepperpot" splint but little improvement resulted.

Thinking along the same lines, I introduced the largely fenestrated splint (Fig. 1). Another objection to the original splint was its thickness, as this caused

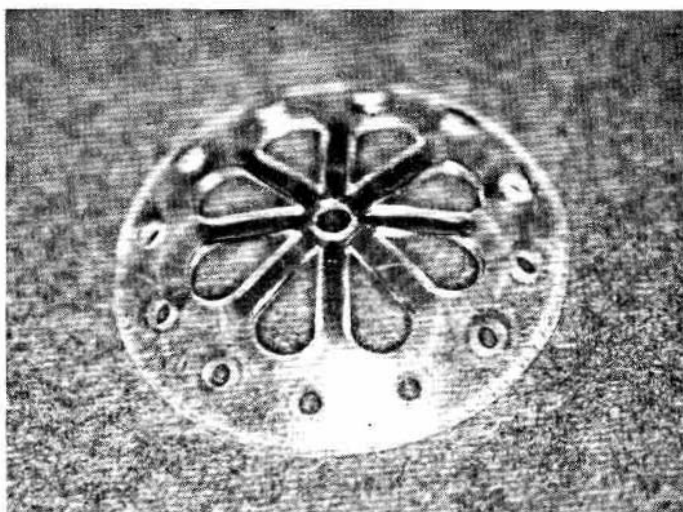


Fig. 1. The splint

undue discomfort to the patient and also led to earlier loosening of the sutures. Therefore, at the same time as altering the pattern, the thickness was reduced.

The improvement using the new splint was very marked but in retrospect it seems unlikely that this was due entirely or even mainly to the access of tear fluids to the graft. The introduction of the large fenestrations and the simultaneous decrease in thickness produced a pliable instead of a rigid splint.

An essential feature of the splint is that it should be springy and not rigid. With such a splint results became satisfactory though elevation of the graft edge occurred occasionally.

## CORNEAL GRAFTS

The original Philips splint had an inside radius of curvature of 3.5 mm, which corresponds approximately to the peripheral cornea, though it tends to be a little too curved. Frequently, however, this radius is considerably too small since scarred corneae are often flatter than normal.

The use of a splint with too great a curve inevitably leads to an elevated graft. It is important that the splint should fit as exactly as possible and to this end, splints should be available with radii of curvature increasing in steps of 0.1 mm, and the most appropriate curve should be selected prior to the operation. It is useful to check the fit with the operating microscope. The most usual range of curves required is from 3.5 mm. to 9.00 mm. At the present time work is proceeding with a view to providing exactly fitting splints made individually for each patient. This is being done in conjunction with Mr. Montague Ruben at the Contact Lens Department of Moorfields Eye Hospital.

The splint should be fixed by four tangential sutures (Figs. 2 and 3) and this will lead to very satisfactory healing provided the sutures are accurately

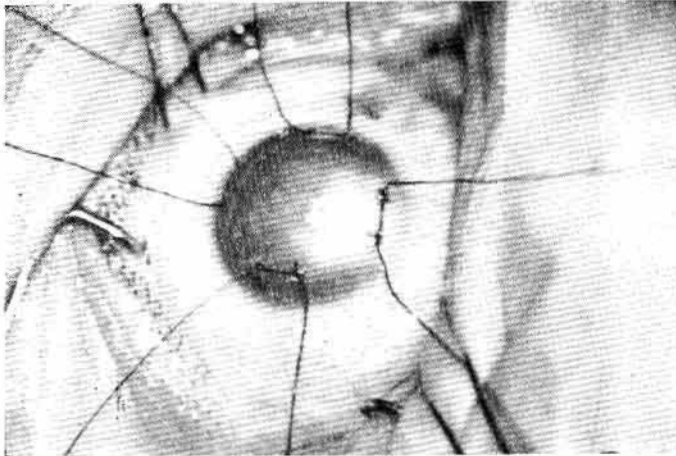


Fig. 2. Tangential sutures in place

placed. The placing is facilitated by a special maker. (Fig. 4). Fig. 5 shows the graft in place under the splint in the same case as Figs. 2 and 3. Little irritation is caused by the splint and it may remain in place for five weeks. The exact length of time for which the splint should remain varies with the type of case.

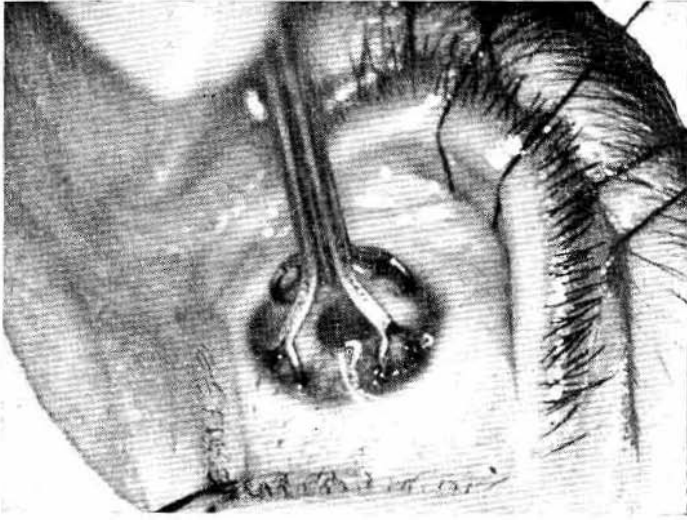


Fig 3. Marker on eye. The eight points, dipped in methylene blue, mark the positions for the suture and facilitate insertion.

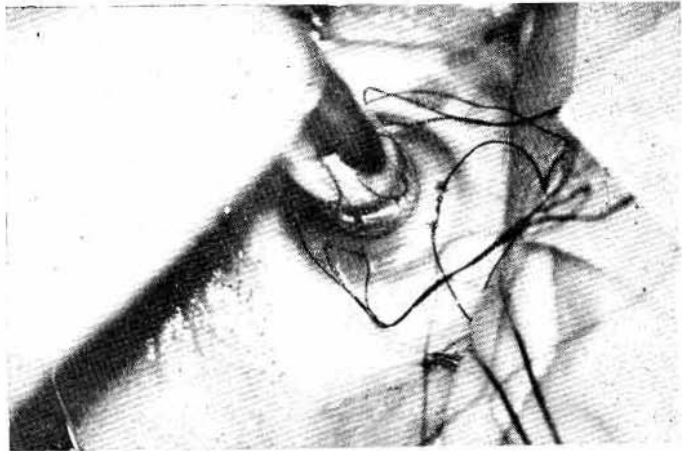


Fig. 4. Trephining past the preplaced sutures.

## CORNEAL GRAFTS

For example, as little as three weeks may be adequate for interstitial keratitis, but at least five weeks

Usually the splint starts to loosen slightly at about four weeks and may be easily removed after this. After cutting the sutures and before lifting the splint an attempt should be made to rotate it gently with a probe. If it does not rotate freely it should not be removed but left in position and the eye repadded. After twenty-four hours the splint will be found to rotate freely and can be removed easily.

If possible a penetrating graft should be kept to a size of seven millimetres or less because eye is more severe in a graft larger than this. Grafts over seven millimetres seldom show a severe reaction while with those of over eight millimetres a reaction is almost inevitable. In addition, in vascularized cornea, spread of vessels to the

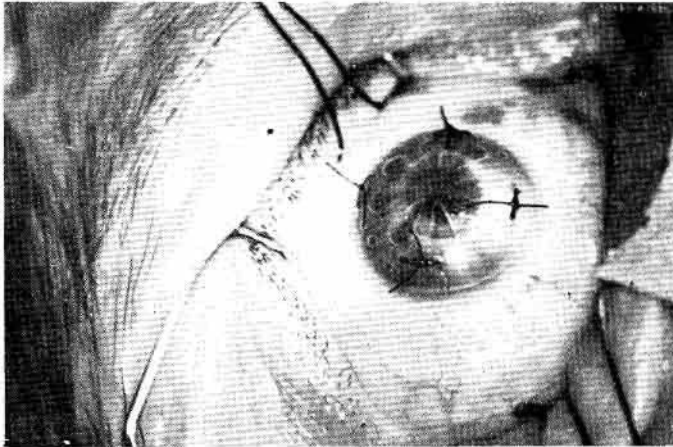


Fig. 5. The four sutures securing the splint over the graft.

graft occurs more readily the larger the graft. Thus where a penetrating graft is required in a vascularized cornea, it is especially desirable to perform a small graft whether a preliminary lamellar graft has been performed or not.

Under these circumstances, a very small graft of less than six millimetres may be the most likely to remain clear. In such grafts edge to edge sutures may encroach on the optical zone it is a great advantage to use a splint. The splint can be used successfully for grafts up to eight millimetres but edge to edge sutures are generally superior where the graft exceeds seven millimetres. With

grafts of diameter six millimetres to seven millimetres either splint fixation or direct suturing give equally good results. The most satisfactory method of direct suturing is to insert from four to eight interrupted sutures followed by a continuous suture.

Hitherto the suture material used has been entirely seven strand virgin silk but quite recently I have had the opportunity to try 10/0 perlon. Best results appear to be obtained using virgin silk for the interrupted suture and perlon for the continuous. The former can be removed after two weeks while the perlon should remain for at least six. It promotes much less reaction than the silk and can, therefore, be left much longer without causing tissue damage.

The fundamental basis of graft fixation should be to achieve good position of the graft relative to the cornea, to fix it firmly, and at the same time to minimize trauma to the graft. In my experience, for grafts of a diameter of six millimetres or less, these conditions are always best met by a splint.

#### SUMMARY

1. The development of a method of splint fixation for small corneal grafts is described.
2. The indications for the use of this method as opposed to edge to edge sutures are discussed.

#### REFERENCES

- QUERATOPLASTIA. Barraquer Moner, J. L. *Estudios e Informaciones Oftalmológicas*, (1948), 1, 10.
- SAFETY TECHNIQUE IN PENETRATING KERATOPLASTY. Barraquer Moner, J. L. *Trans. Ophthalm. Soc., U. K.*, (1949), 49, 77.
- CORNEAL GRAFT FIXATION AND ITS RELATION TO ASTIGMATISM. Philips A. S. and Finckham, E. F. *Trans. Ophthalm. Soc., U. K.* (1952), 72, 21.

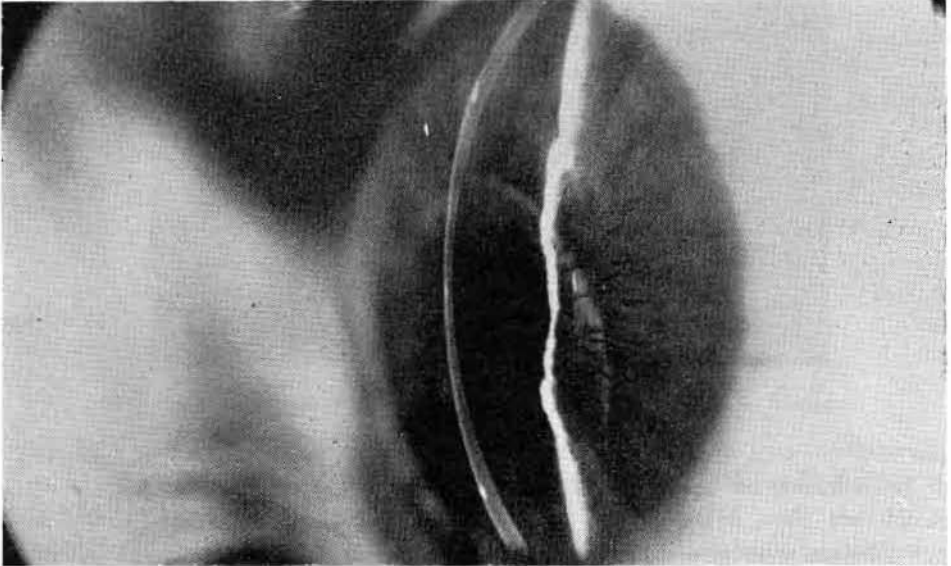
37, Harley Street

\* Figs. 1 and 4: originally published in *Trans. Ophthalm. Soc., U. K.*, 1959, 79, 209.

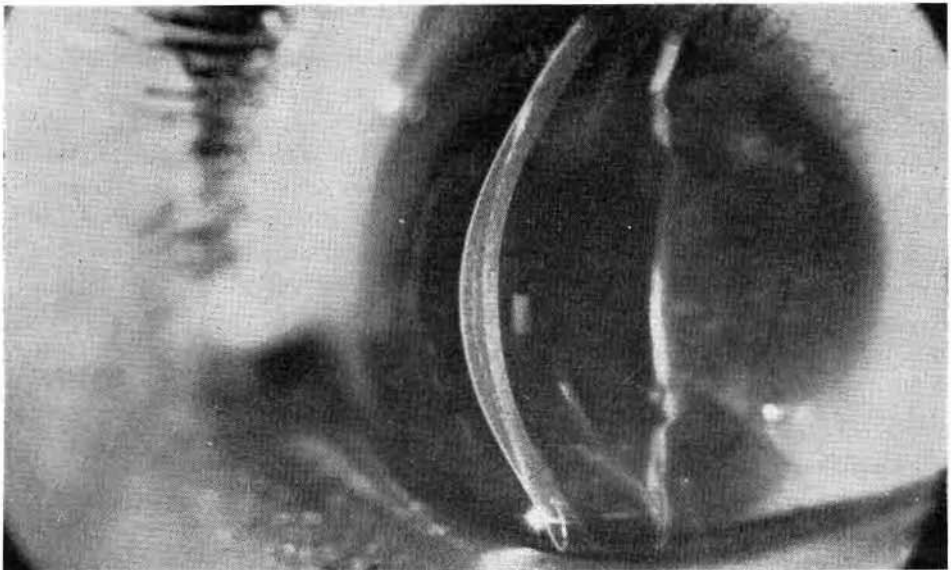
## QUERATOPLASTIA REFRACTIVA

POR

JOSE I. BARRAQUER, M. D.  
Bogotá - Colombia



A) Keratomileusis. Corrección  $-18.00$  Dioptrías en vértice.



B) Keratofaquia. Corrección  $+15.00$  Dioptrías en vértice.

## INTRALAMELLAR HOMOPLASTY FOR THE PURPOSE OF RELAXATION OF REFRACTION OF THE EYE \*

BY

E. D. BLAVATSKAYA. M. D.

Yerevan, USSR.

The first attempt to correct myopia by means of surgery was made by Fukala (1890, 1896). His proposed operations were not successful and were discarded due to their heavy consequence. Only after more than 50 years, with the perfection of surgical technique, individual authors once again turn to the removal of transparent lens in the case of high short-sightedness (Valerio, 1953, Salgado, 1954).

Operations, having the purpose of eliminating or lessening short-sightedness, can be joined to three main groups: 1) the shortening of the eye's axial length by the resection of the sclera; 2) introduction to the anterior chamber of the eye artificial lens with diffractive action; 3) reduction of the curvature of the anterior surface of the cornea. All of these operations are now in the stage of experimental cultivation and study, operations on people are few. Surgical intervention of the cornea is less dangerous, than, the introduction of intra-cameral lens or resection of the sclera, as, basically it is not connected with the dissection of the eye. Besides which, the leading role of the cornea in the dioptric system of the eye, the availability of studying its optical properties establish wide possibilities for modifying various types of surgical intervention and, what is especially important, the degree of refractionary changes in the required limits.

\* Translation of the article published in U.S.S.R. Journal Ophthalmological, 1966, № 7, pp. 530-537.

The purpose of refractory operations of the cornea comes to the change of the curvature of its anterior surface at the same time preserving its full transparency. Such operations are lamellar auto-keratoplasty operations (Barraquer, 1958, 1961), the flattening of the cornea by incision of the posterior surface (Sato, 1953), cutting the peripheral ring of the anterior layers of the cornea (Payales, 1950; Pur, 1957; Barraquer, 1949), keratectomy (Strampelli, 1964), stromectomy (Krwawicz, 1963, 1964), keratomileusis (Barraquer, 1964, 1965) and others.

Operations of intralamellar grafts of the cornea are cultivated, mainly, for the intensification of the eye's refraction by aphakia (Barraquer, Krwawicz, Kashouk and Morkhat, 1961). Investigation of various theoretical variations of intralamellar keratoplasty with the intent of changing the refractive power of the eye, Barraquer produced up to 18 diagrams, among which is the diagram of the graft, having the form of rings, introduced to the stroma of the cornea through the anterior surface. According to Barraquer such keratoplasty should bring the flatness of the cornea, that is a negative effect. Although Barraquer himself did not use that type of keratoplasty neither in experiments nor on patients.

Engaged in refractory keratoplasty with the aim of changing the refractive power of the eye (E. D. Blavatskaya, 1964, 1965), we had the possibility of convincing ourselves of the preservation of the transparency of the cornea after its extoliation and transplant healing of the inner corneal graft, on the condition of isolating it and the injured bed, from the effect of tears and conjunctive detachment. Good, almost without reactionary healing of inter-lamellar homotransplants in experiments on rabbits served as a basis for explorational operations with the aim of relaxing the refractory power of the eye. The decrease of the curvature of the anterior surface of the cornea in suggestions up to present operations have been reached by thinning the cornea in its optical zone (keratectomy, stromectomy, keratomileusis). We were able to receive the same effect by another method: not changing the thickness of the cornea in its central part, lessens the refractive strength by introducing to the stroma the transplant in form of rings.

Judging by literary sources, such types of operations, up to the present have not been conducted by anyone.

Theoretically there are three possible variations for the alteration of the corneal curvature, by use of ring transplants: the surface of its central parts become: 1) less spherical, 2) flat, 3) concave (Fig. 1 a, b, c). The degree of the change of the curvature of the cornea in the optical zone depends on the thickness of the ring and size of its diametrical aperture. Consideration should

INTRALAMELLAR HOMOPLASTY

be also taken of the change of the configuration of the ring after grafting. We were convinced of the change of forms of inter-plastic grafts, when, just at the first days after the operation the peripheric parts of the ring were seen on the histologic section. The ring on the whole lost its previous form and took the

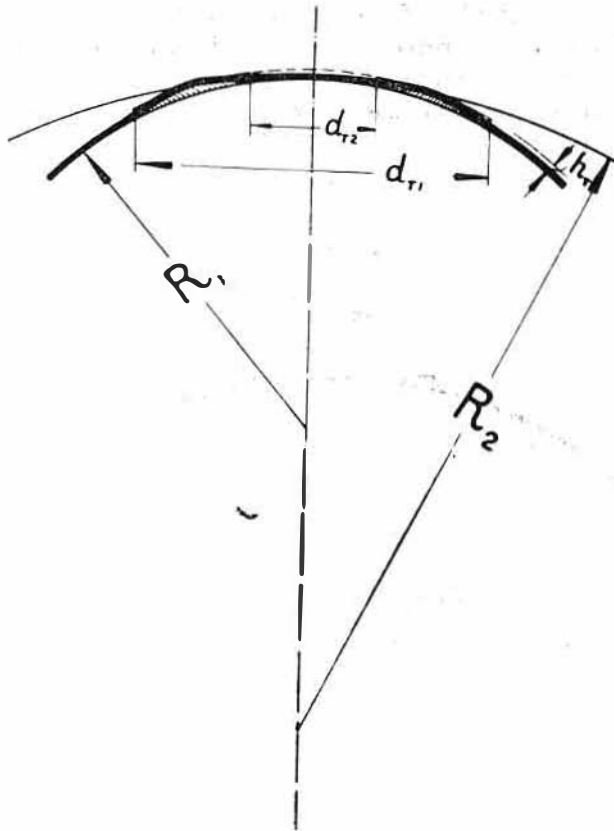


Fig. 1. A diagram of the change of the curvature of the anterior surface of the cornea after grafting rings: a- the surface of the cornea becomes less spherical; b) flat; c) corneave.

appearance of two lens. The forming power is above all the corneal plastic tension, its pressure on the transplant. Under the effect of the forming power of the cornea the smoothing of "corners" of the outer and inner border of the

ring takes place. Significance in the changes of the forms of the ring rests not only in the thickness, but in the width.

So as to ascertain in experiments, what optical results may be achieved by intra-lamellar transplant rings, we undertook two basic groups of experiments: in the first group (16 operations) went the transplantation of rings of all thickness of the donar's cornea, sizes  $4 \times 7$  mm and  $5 \times 8$  mm; in the second (22 operations) — the grafting of rings of various thicknesses from the anterior and posterior layers of the cornea. The eyes of rabbit just killed served as material for transplants. Before the operation the epithelium of the cornea was thoroughly scraped off to avoid allergic reactions and formation of epithelial

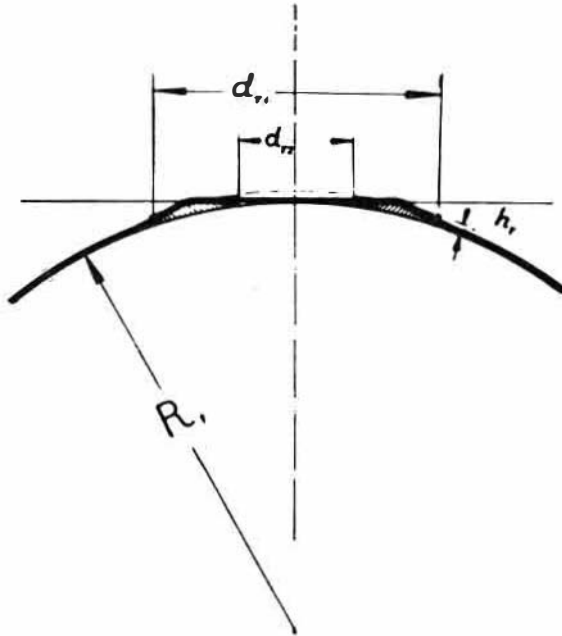


Fig. 1 b

cyst (V. V. Vojno-Yasenetsky, 1958; V. C. Bellayev, 1963) and the grafts were cut out with a trepan of suitable diameters. By taking the ring from the layer of the cornea it was preliminarily divided into layers by spatula or curved knives.

The technique of the operation consists of the following: after hypodermic injections 0,5 ml 1% of promidol solution, then retrobulbar injections are given

INTRALAMELLAR HOMOPLASTY

of 2,0 ml 0,5% solution of novocaine; the eyeball is dislodged and a gauze napkin is fixed. At 1 — 2 mm below the limbus a horizontal or slightly arched incision of the cornea approximately at the middle of its thickness takes place. In the "pocket" the graft in the form of a ring is introduced, and it is carefully arranged so, that its opening strictly coincides with the optical zone. At the lip

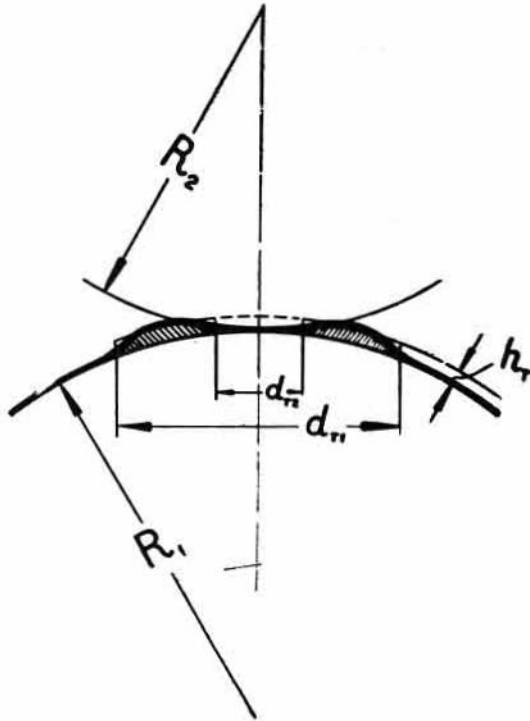


Fig. 1 c

of the wound 3 or 4 resorptive stitches are laid. Installation of 1% atropine solution and 30% albusid solution, injections of 30.000 ed. penicillin under conjunctive sclera. In the period of 5-6 days after the operation — instillation of atropine and albusid once a day.

With the use of Rodenstok's skiascopy and refractometers, the general refraction of the eye was examined before the operation; the radius of the curvature of the anterior surface of the cornea by ophthalmometer and the thickness of the cornea in the optical zone with the help of a prefix on the slit lamp, sug-

gested by I. A. Viazovsky (1960). Studies were repeated at various intervals after the operation, besides which, keratograms by the perfected method of E. G. Shaer (1962), and photographs of optical sections of the eye meridians by the method suggested by A. I. Dashevsky (1952), and Viazovsky (1956, 1961).

A great part of the experiments took place at the Odessa Institute for the Diseases of the eye and Tissue Therapy named after V. P. Filatov. Photograms of the optical sections of the cornea were taken by the Institute's Scientific worker I. A. Viazovsky. Keratograms and profile photographs of the rabbit's eye were made in the Institute's photolaboratory by E. G. Shaer.

In all, 45 operations on 36 rabbits were performed (9 rabbits were operated on both eyes), of which 3 rabbits (2 of which were operated on both eyes) in the first 24 hours a sharply expressed inflammatory process arose from the conjunctive sides of the cornea and iris, the result of which was that the cornea dimmed and blood vessels developed. In the cultivated material these three rabbits were not included as, still another was operated on both eyes and died the first day after the operation. In that case, in the real work the results of 38 operations were studied, performed on 32 rabbits. The healing of the transplants of these rabbits was smooth, without any kind of accessory inflammatory appearances; as a rule, at the openings of and around the graft and cornea, there was a slight opalescence in the first 2 - 3 days, then the detection of the graft was made possible only by special study; the surface of the cornea remained smooth.

Let us lead to the further analysis, reached after grafting rings of various thickness and diameters.

1. Configuration of the anterior surface of the cornea changes after the grafting of rings, the flattening corresponding to the ring openings. This flattening in most cases arose immediately after the introduction of the ring in the thickness of the cornea and at the laying of stitches on the wound. The flattening effect in the central part of the cornea remained during the whole term of study of the operated rabbits and are visible on the customary profile photographs (Fig. 2, 3). Changes of the configuration of the cornea are clearly visible on the histologic sections and photograms of the optical sections of the cornea. Studies of the histologic sections and especially photograms of the optical sections confirmed our theoretical assumptions of the three possible types of changes of the anterior surface of the cornea after introducing ring grafts to its surface. On the histologic sections received in the early days after the operations, the change of the ring forms were clearly seen: they do not have a cylindrical form by any of the sections: the sharp edges of the ring were

INTRALAMELLAR HOMOPLASTY

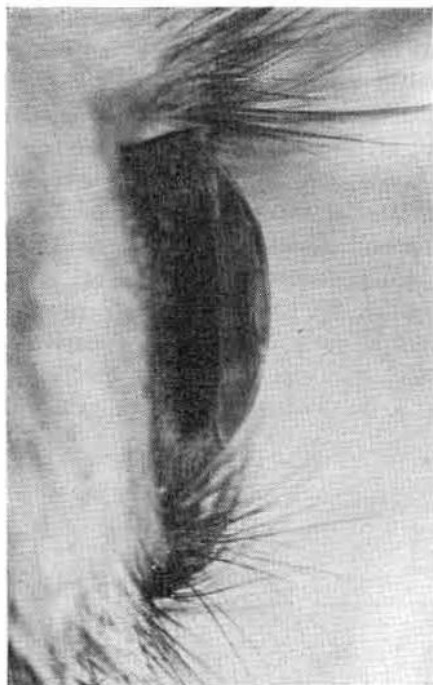
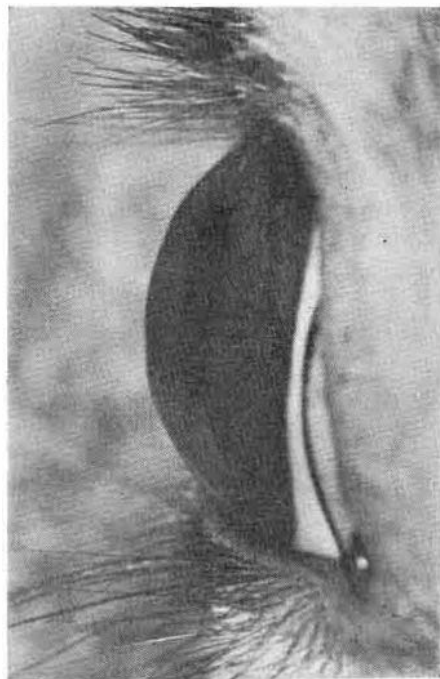


Fig. 2. Rabbit 34, right eye. General refraction of the eye after the operation - hypermetropia 11, OD, the surface of the cornea flattened.

Fig. 3. Rabbit 883, right eye. General refraction of the eye after the operation - hypermetropia 7, OD. The cornea is flattened in the central parts, at the place of the ring graft-elevated.



laid the same, in the internal, as in the external limits. During the examination of the rabbits operated eye, in some cases our attention turned to rather distinct elevations, corresponding to the inner rim of the ring. Usually it is noticeable after grafting the ring from the full thickness of the cornea. On histologic section it is seen that these elevations are formed on account of the thickening of the stroma, the anterior walls of the "pocket" of the cornea and its epithelium. The edge of the rings are in these cases sloping, and thinner. Various types of configuration changes of the anterior surface of the cornea after grafting the rings, are in direct dependence of the size and thickness of the rings. This is especially clear in the photograms of the optical sections of the cornea, produced for radius studies of the corneal curvature. So, the flatness or apparent flatness of the surface of the cornea in its central parts (type II were received by grafting rings 4 x 7 mm in the full corneal thickness, that is by grafts of medium thickness, equal to 0.25 - 0.32 (Fig. 4, 5). Photograms of the rabbit's




Fig. 4. Rabbit 395, right eye. Photogram of the optical section of the cornea. Corresponding aperture of the ring of the cornea is flattened. Hipermetropy 20, OD.

Fig. 5. Rabbit 733, right eye. Photograph of the optical section of the cornea. The anterior surface of the cornea's corresponding aperture of the ring is flat. Hypermetropia 20, ●D.



cornea with transplants of rings 5 x 8 mm also of full thickness, appear otherwise. Here, type I prevails, that is in the central part of the corneal corresponding opening of the ring, equal to 5 mm, although flat, by clearly guarding its protruding surface (Fig. 6). When grafting rings of sizes 4 x 7 mm, but two times thinner, the change of the configuration of the cornea always corresponds with type I (Fig. 7, 8).

Keratograms, received of the cornea with intralameLLar ring transplants, have a special, typical form (Fig. 9, 10). The central circles of the keratograms are increased in diameter and are evidence of the relaxation of the cornea sphere, subsequently, between the rings, appearances as of ruptures, are noticeably remote; in those parts they correspond to narrow furrows on the surface of the cornea at the inner limits of the grafted rings. The rings of keratogram reflecting from flat or slightly protruding surfaces, lose their clearness, the distance between them increases by many times. Then come circles, reflecting the increase of the curvature of the cornea, corresponding to the arrangement of

the place of the grafted rings. Here the rings are condensed, narrow, smaller in diameter. Keratograms make it possible to judge not only the sphere, but and of the smoothness of the surface of the cornea and of the restoration at remote periods after the operation.

2. The radius of the corneal curvature of all of the operated rabbits increased in the field of the aperture of the ring, corresponding with the optical zone.

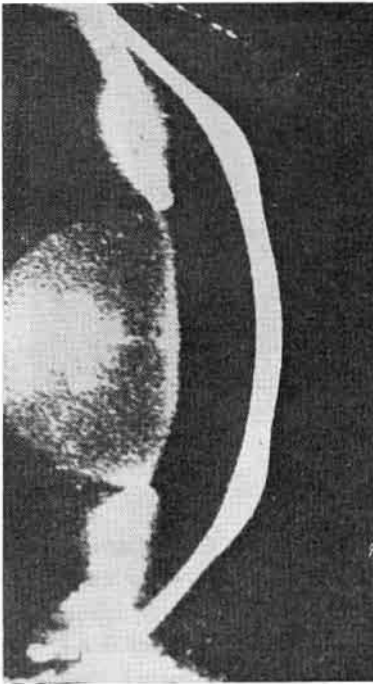


Fig. 6. Rabbit 403, right eye. Photogram of the optical section of the cornea. Corresponding aperture of the ring in the anterior surface of the cornea is flattened. Hypermetropia 16, OD.

Studies of the radius of the corneal curvature were made by using ophthalmometry and demanded special skill, as it was important to center the apparatus on the aperture of the ring. That was possible thanks to the correspondence of the diameters of the optical zones, the operation of the transplanted rings and the technical data of the apparatus, intended for studies of the spherical surface on parts of 3 mm. in diameter. The normal size of the radius of the rabbit's corneal curvature for the given groups of experimental animals were within the limits of 6,13 to 7,05, with the predominant curvature of 6,57 - 6,64.

INTRALAMELLAR HOMOPLASTY

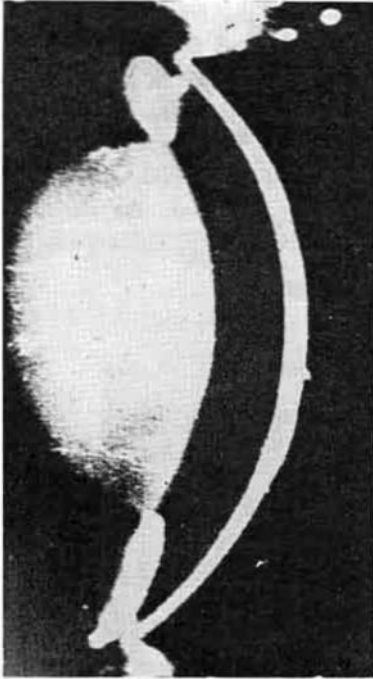


Fig. 7. Rabbit 833, right eye. Photogram of the optical section of the cornea. The cornea flattened, the general configuration is spherical. Hypermetropia 7, OD.

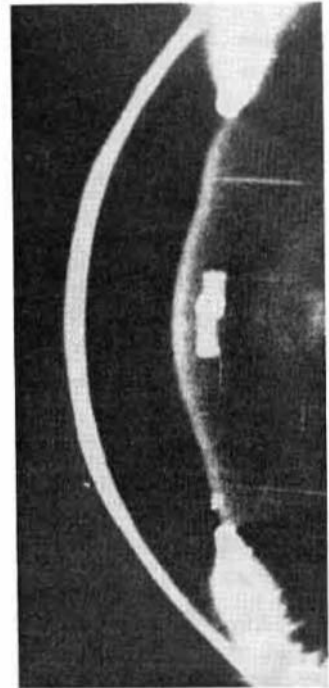


Fig. 8. Rabbit 364, right eye. Photogram of the optical section of the cornea. The cornea is flattened, the general configuration is spherical. Hypermetropia 10, OD.

Among the operated rabbits the maximum increase of the radius of the corneal curvature of the anterior surface of three rabbits after the transplants of rings  $4 \times 7$  and equaled to 10,05. The grafted rings had 0,29 and 0,30 mm thickness. By grafting rings of the same thickness, but of  $5 \times 8$  diameters, the radius of the corneal curvature increased from 8,3 to 9,35 in 5 eyes. The same figures were reached by grafting rings of  $4 \times 7$  mm thickness fo 0,13 — 0,16 mm. The radius of the corneal curvatures by transplanting rings of  $6 \times 8$ , thickness of 0,12 — 0,14, were practically uncharged. Apparently, not only the theoretical but and the practical possible variations, when the curvature of the cornea after

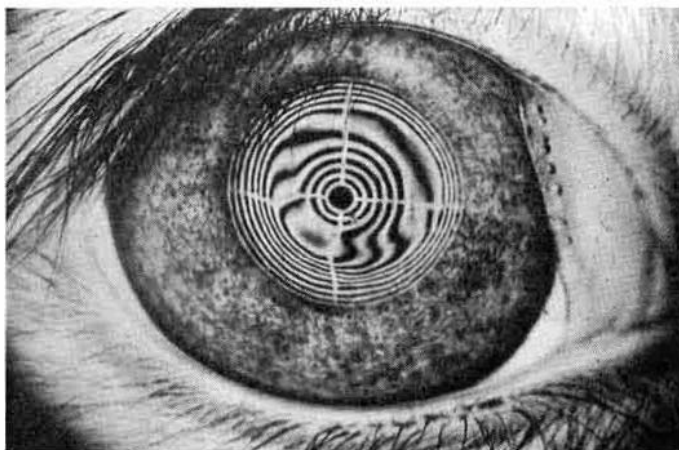


Fig. 9. Rabbit 34, right eye. Keratogram. The circles disperse according to the aperture of the ring. Hypermetropia II, OD.

transplant of rings do not change. Then as the table of corresponding radius of the curvatures and refractive powers of the anterior surface of the cornea compiled in the estimate on the co-efficient of the refractive man's cornea, we were contented with only the data of the radius of the curvatures.

It ought to be noted, that astigmatism when studied by ophthalmometer was noticed among few rabbits and was insignificant.

3. After grafting the rings, the thickness of the cornea was altered. The average thickness of the central zone of the cornea for the given groups of rabbits varied within the limits of 0,30 to 0,38. After grafting the thickness

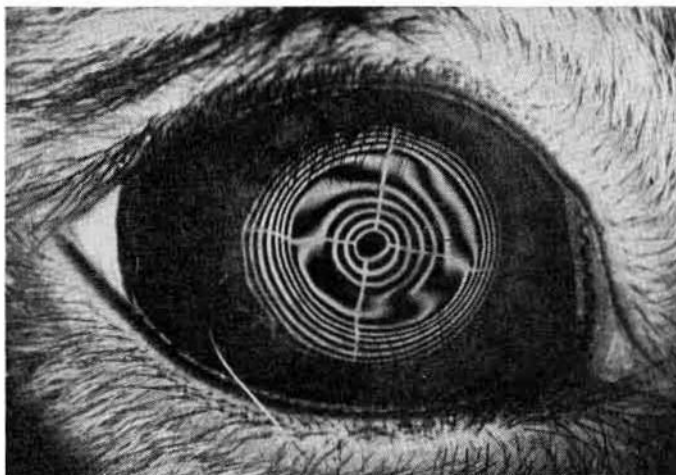


Fig. 10. Rabbit 696, right eye. Keratogram. Hypermetropia 9, 01).

of the center of the cornea did not change (difference of  $\pm 0,01 - 0,02$  were within the limits allowed for mistakes). On the contrary, the thickness of the cornea on the rings without large deviations corresponded with the figures of the graft's thickness and the owner's cornea. With noticeable difference in the thickness of the cornea in comparison with the outcome, it was usual possible to discover the cause of differences: crevices in the cornea layer, oedema of the stoma of the cornea or transplant.

We bring in the form of examples data on the measurements of the thickness of the cornea of several rabbits: rabbit 450, right eye, thickness of the corneal center 0,33; the grafted ring 4 x 7 mm from the anterior layer of the cornea, thickness of 0,1 — 0,12 mm. Two weeks after the operation the thickness of the cornea in the center 0,34, on the ring 0,46. Rabbit 403, right eye, thickness of the cornea in the centre 0,38, grafted rings 5 x 8, thickness 0,37; two weeks after the operation — thickness of the cornea in the center 0,38; on the ring 0,70. Rabbit 395, left eye, thickness of the cornea in the center 0,35; grafted ring 4 x 7, thickness 0,30; two weeks after the operation the thickness of the cornea in the center 0,55, on the ring 0,90. In the light of the spalt-lamp a slight diffused lees of the graft and cornea in the aperture of the ring and surroundings, apparently, on account of the oedema was noticed.

4. The general refraction of the eye of all the rabbits relaxed, definite connection between the sizes of the grafted rings and degrees of the relaxation of the general refraction were noticed.

By grafting rings with diameters from  $4 \times 7$  to  $6 \times 8$ , in thickness from 0,31 to 0,1 it was possible to obtain the relaxation of refractions within wide limits: the maximum of 21,0 d. and the minimum of 1,5 d. Rabbits with grafts of  $4 \times 7$  in the full thickness of the cornea (from 0,27 to 0,30 - without the epithelium) hypermetropia arose from 23,0 to 14,0 d., or of calculations made of the hypermetropia place before the operation, refraction of the eye relaxed from 21,0 - 12,0 d. The refractive relaxation of 12,0 d. was noticed in one case only in the remaining seven it was from 21,0 (both eyes) to 18,5 d. (also both eyes).

The grafting of ring the sizes of  $4 \times 7$  mm and thickness from 0,24 to 0,1 was performed on 11 eyes. The general refraction of the eye relaxed to 16,5 d. with rings of 0,24 thickness; those of 0,15 - 0,17 thicknesses to 12,0 - 9,0 d. The transplanting of rings of 0,1 - 0,12 mm thickness gave the most uniform results: the refractive relaxation was within the limits of 8,5 - 7,5 d.

A markedly greater wavering in the change the refraction of the eye in further grafts of rings of  $5 \times 8$  mm. diameters taken from the full thickness of the cornea was seen: relaxation of refraction was noticed within the limits of 14,0 to 5,0 d. Upon analysis of the data received, the knowledge of the thickness of the transplanted cornea served a great help, measured as a rule, before the donar's death. It appeared, that a great range in the results by grafting rings  $5 \times 8$  mm have a certain tie with various thickness of the donar's cornea. So, relaxed refractions of 14,0 - 12,0 and 11,5 d. were noticed after ring transplants of 0,31 mm thickness. On the contrary, rings  $5 \times$  with the thickness of 0,28, 0,25 and 0,23 mm gave relaxed refractions of 8,0 and 7,0 d.

For the general results of the changes of the refraction of the rabbit's eye by interplasty of ringed grafts, it is essential to note the following: transplants in the form of ring cause the flattening of the anterior surface of the cornea, increasing the radius of its curvatures, and relaxation of the general refraction of the eyes. There exist certain rules of the degrees of relaxation of refraction, depending on the geometric sizes of the transplants: rings or large diameters cause less relaxation of the eye refraction; thinning of transplants of the same diameters cause less relaxation of refraction.

Optimum sizes of the grafted ring, apparently, are rings  $4 \times 7$  mm, rings with smaller inner diameters occupy a field smaller than the optical zone. Rings of greater diameters are placed in the pocket of the split cornea with noticeable greater difficulty and are especially placed 50, as to defend the correct form of the circle. Taken as optimum sizes of the ring graft, the diameter  $4 \times 7$  mm and changing its thickness, it is possible to relax the refraction of the eye from 21,0 to 6,0 - 7,0 d., Conditionally we may accept, that the relaxation of the

By grafting rings with diameters from 4 x 7 to 6 x 8, in thickness from 0,31 to 0,1 it was possible to obtain the relaxation of refractions within wide limits: the maximum of 21, Od. and the minimum of 1,5 d. Rabbits with grafts of 4 x 7 in the full thickness of the cornea (from 0,27 to 0,30 - without the epithelium) hypermetropia arose from 23,0 to 14,0 d., or of calculations made of the hypermetropia place before the operation, refraction of the eye relaxed from 21,0 - 12,0 d. The refractive relaxation of 12,0 d. was noticed in one case only in the remaining seven it was from 21,0 (both eyes) to 18,5 d. (also both eyes).

The grafting of ring the sizes of 4 x 7 mm and thickness from 0,24 to 0,1 was performed on 11 eyes. The general refraction of the eye relaxed to 16,5 d. with rings of 0,24 thickness; those of 0,15 - 0,17 thicknesses to 12,0 - 9,0 d. The transplanting of rings of 0,1 - 0,12 mm thickness gave the most uniform results: the refractive relaxation was within the limits of 8,5 - 7,5 d.

A markedly greater wavering in the change the refraction of the eye in further grafts of rings of 5 x 8 mm. diameters taken from the full thickness of the cornea was seen: relaxation of refraction was noticed within the limits of 14,0 to 5,0 d. Upon analysis of the data received, the knowledge of the thickness of the transplanted cornea served a great help, measured as a rule, before the donar's death. It appeared, that a great range in the results by grafting rings 5 x 8 mm have a certain tie with various thickness of the donar's cornea. So, relaxed refractions of 14,0 - 12,0 and 11,5 d. were noticed after ring transplants of 0,31 mm thickness. On the contrary, rings 5 x with the thickness of 0,28, 0,25 and 0,23 mm gave relaxed refractions of 8,0 and 7,0 d.

For the general results of the changes of the refraction of the rabbit's eye by interplasty of ringed grafts, it is essential to note the following: transplants in the form of ring cause the flattening of the anterior surface of the cornea, increasing the radius of its curvatures, and relaxation of the general refraction of the eyes. There exist certain rules of the degrees of relaxation of refraction, depending on the geometric sizes of the transplants: rings or large diameters cause less relaxation of the eye refraction; thinning of transplants of the same diameters cause less relaxation of refraction.

Optimum sizes of the grafted ring, apparently, are rings 4 x 7 mm, rings with smaller inner diameters occupy a field smaller than the optical zone. Rings of greater diameters are placed in the pocket of the split cornea with noticeable greater difficulty and are especially placed 50, as to defend the correct form of the circle. Taken as optimum sizes of the ring graft, the diameter 4 x 7 mm and changing its thickness, it is possible to relax the refraction of the eye from 21,0 to 6,0 - 7,0 d., Conditionally we may accept, that the relaxation of the