

ARCHIVOS
DE LA
SOCIEDAD AMERICANA
DE
OFTALMOLOGIA Y OPTOMETRIA

SUMARIO

	Página
PRIMUM FORUM OPHTHALMOLOGICUM	207
SESION INAUGURAL	209
H. HARMS, M. D.	
PALABRAS DEL PRESIDENTE DEL PRIMUM FORUM OPHTHALMOLOGICUM	211
LECTURA DEL ACTA DE LA CONCESION DE LA MEDALLA IGNACIO BARRAQUER Y BARRAQUER	213
ENTREGA DE LA MEDALLA IGNACIO BARRAQUER Y BARRAQUER E INAUGURACION DEL PRIMUM FORUM OPHTHALMOLOGICUM POR EL EXCELENTISIMO SEÑOR PRESIDENTE DE LA REPUBLICA, DOCTOR CARLOS LLERAS RESTREPO	215
H. HARMS, M. D.	
SUTURES IN KERATOPLASTY AND CATARACT	219
TADEUSZ KRZAWICZ	
CRYOEXTRACTION OF CATARACT AND ITS INFLUENCE ON THE DEVELOPMENT OF CRYO-OPHTHALMOLOGY	231
HANS LITMANN, PH. D.	
OPTICS OF KERATOPLASTY	249
NOTICE	257

ARCHIVOS DE LA SOCIEDAD
AMERICANA DE OFTALMOLOGIA
Y OPTOMETRIA

INSTITUTO BARRAQUER DE AMERICA

ARCHIVOS
DE LA
SOCIEDAD AMERICANA
DE
OFTALMOLOGIA Y OPTOMETRIA

Vol. 8

1971

No. 3

SECRETARIO GENERAL Y DE REDACCION:
SALOMON REINOSO A., M. D.
APARTADO NACIONAL 700/2
BOGOTA - COLOMBIA

PRIMUM FORUM OPHTHALMOLOGICUM

Lunes 16 a Viernes 20 de Marzo de 1970

Bogotá - Colombia

PRESIDENTE DE HONOR

Prof. H. Harms
Tubingen - Alemania

JUNTA LOCAL

DIRECTOR EJECUTIVO

Dr. José I. Barraquer

SECRETARIO EJECUTIVO

Dr. Salomón Reinoso

TESORERO

Dr. Carlos Téllez

PROGRAMAS CIENTIFICOS

Dr. Francisco Barraquer

TELEVISION Y PROYECCIONES

Sr. Ignacio Barraquer
Dr. Zollo Cuéllar

TRADUCCION SIMULTANEA

Dr. Gustavo Scioville
Dr. George Assis

SESIONES QUIRURGICAS

Dr. Zollo Cuéllar
Dr. Angel Hernández
Sta. Carmen Barraquer

SESIONES CLINICAS

Dr. Enrique Ariza
Dr. Alberto Reinoso

EXHIBICION CIENTIFICA

Dr. Gabriel Merchán
Dr. Wolfgang Schmidt

INSCRIPCION

Dr. Hernando Henao
Dr. Fabián Martínez

RECEPCION

Dr. Hartmut Weber
Dr. Gustavo Scioville
Dr. Nariño Pérez J.

RELACIONES PUBLICAS
Y PRENSA

Dr. Vicente Rodríguez
Sr. Ignacio Barraquer
Dr. Gustavo Scioville

EVENTOS SOCIALES

Dr. Enrique Ariza
Dr. José Ma. Silva

PROTOCOLO

Dr. Jaime Téllez
Dr. Hernando Castro
Dr. Gabriel Merchán

EXHIBICION COMERCIAL

Dr. Alberto Reinoso
Dr. Salomón Reinoso

COMITE DE DAMAS

Sra. Margarita Coli de Barraquer

ACOMODACION Y
TRANSPORTE

Sr. Fernando Uribe

SESION INAUGURAL
PRIMUM FORUM OPHTHALMOLOGICUM
LUNES 16 DE MARZO DE 1970

I—PALABRAS DEL PRESIDENTE DEL INSTITUTO
BARRAQUER DE AMERICA DR. JOSE I. BARRAQUER.

Excelentísimo Señor Presidente de la República, Doctor Carlos Lleras Restrepo. Excelentísimo Profesor Harms, Presidente del Primum Forum Ophthalmologicum. Ilustrísimos Miembros de Honor. Señoras, compañeros, señores:

Es para mí altamente honroso, el dirigirm
mi más cordial saludo de bienvenida, así como también hacerlo en nombre del Instituto Barraquer de América y de la Sociedad Americana de Oftalmología y Optometría, con ocasión de este acto inaugural del Primum Forum Ophthalmologicum, primero de una serie de Foros, que a juzgar por la numerosa y selecta concurrencia, serán de indudable utilidad para todos nosotros, para el progreso de la oftalmología y para estrechar aún más los vínculos ya apretados de amistad y compañerismo del mundo oftalmológico.

Los temas que principalmente se discutirán en este foro son dos, el primero, antiguo pero siempre de candente actualidad, dada su trascendencia para nuestros pacientes y especialmente actualizado por la introducción de un nuevo método quirúrgico: La Cryoextracción de Krwawicz. El otro, muy joven aún, está en la mente subconsciente de la oftalmología desde hace muchos años y en la que fue introducido por el anhelo de miles de pacientes que desean mejorar su capacidad de visión y prescindir del uso obligatorio de aditamentos protésicos, por muy perfectos que éstos sean. Esta meta solo parcialmente alcanzada y el estudio del estado actual de métodos convenientes y caminos a seguir en el futuro, es otra de las razones que nos han

PRIMUM FORUM OPHTHALMOLOGICUM

congregado, a fin de que de la discusión brote la luz y que nuestras mentes se fecunden mutuamente en provecho de la ciencia y de la humanidad.

Henos aquí venidos de los cinco continentes, reunidos en la cima de esta colina andina, para estudiar por cinco días estos problemas y no dudo, sacar importantes conclusiones.

Seguramente es este uno de los congresos oftalmológicos que se ha realizado a mayor altura y tal vez esta mayor proximidad al universo y a Dios, contribuya a expandir nuestras ideas en pro de nuestros ideales.

Excelentísimo señor presidente de la República, doctor Carlos Lleras Restrepo: Vuestra presencia entre nosotros para inaugurar solemnemente este Primum Forum Ophthalmologicum, es índice del interés de Colombia y su gobierno, por la ciencia y el progreso universal. Con ello prestigiais nuestra reunión y nos estimuláis e infundís el espíritu de servicio que caracteriza vuestros actos.

Bienvenidos todos al Primum Forum y espero de todo corazón, que en sus actividades científicas y sociales, hallareis todo el provecho y amistad que los organizadores han soñado pudieséis encontrar.

2—PALABRAS DEL PRESIDENTE DEL PRIMUM FORUM OPHTHALMOLOGICUM, DR. H. HARMS.

Excelentísimo Señor Presidente de la República, Doctor Carlos Lleras Restrepo.

Señoras, señores:

Para comenzar quisiera agradecerles sinceramente el gran honor que me han conferido al nombrarme Presidente del Primum Forum Ophthalmologicum. Trataré de cumplir con mi deber de la mejor manera posible.

Mi primera y más alta obligación es presentarle mi saludo a usted, Señor Presidente, primer hombre del País del cual somos huéspedes. Nos damos cuenta de la gran distinción y del gran honor que representa para el Primum Forum Ophthalmologicum su presencia, y su presencia aquí nos muestra que Usted comprende que la investigación médica representa una inversión, algunas veces, una inversión muy costosa para el gobierno, pero que ayuda muchísimo para el bienestar de todos y cada uno de los miembros de la nación.

Quizá Usted comparta nuestro sentimiento de que las reuniones médicas internacionales ayudan de cierta manera a la comprensión internacional puesto que no hay ningún sentimiento de competencia, ni de celos, ni de lucha por poder o por malentendidos políticos. Nuestra labor contribuye a la labor que se lleva a cabo en todo el mundo para ayudar a la salud de los pueblos y esta es la razón por la cual nosotros nos damos cuenta de que usted comprende nuestros ideales y nuestras ideas y le agradecemos de todo corazón por ello.

Me corresponde ahora presentarle un saludo a todos ustedes, quienes han venido invitados por nuestro amigo José Barraquer, procedentes de todas partes del mundo y que se han reunido aquí en Bogotá para el Primum Forum Ophthalmologicum; puesto que este es el Primer Forum, debemos

pensar un poco en el sentido y la razón por la cual se ha reunido este congreso.

Cuando leemos los temas principales de este congreso, nos damos cuenta de que aquí se van a analizar dos tipos especiales de cirugía. Todos los que nos hemos dedicado a la Oftalmología no nos vamos a dedicar únicamente a la morfología de los procedimientos quirúrgicos, sino que vamos a sacar todos los procedimientos morfológicos y vamos a ver todos los defectos quirúrgicos que pueden producirse sobre el ojo.

Claro que en el resultado nos dedicamos simplemente a las funciones visuales, pero por otra parte, todos sabemos que hoy en día sin la investigación especializada no se puede progresar, de modo que la primera tarea de un congreso científico tal como este Primum Forum Ophthalmologicum, es hallar la conexión y los eslabones que existen entre las diferentes esferas de investigación científica y mantener la armonía de este edificio científico con nuestro trabajo específico, y sin esa coordinación, nuestra labor no tendría valor.

Estoy convencido de que este Primum Forum Ophthalmologicum puede integrar esta labor y aquí vamos a hablar de cirugía de la córnea y del cristalino y ver los resultados óptimos que se pueden lograr mediante estas intervenciones. Estos problemas son tan importantes para la ciencia médica como para su práctica y deseo que para todos nosotros, los días por venir sean fructíferos y sirvan de ejemplo para nuestros colegas oftalmólogos.

Muchas gracias.

3—LECTURA DEL ACTA DE LA CONCESION DE LA MEDALLA IGNACIO BARRAQUER Y BARRAQUER.

ACTA N° 15

En Bogotá, a los 15 días del mes de Septiembre de Mil novecientos sesenta y nueve y siendo las 6 horas de la tarde, se reunió en la Presidencia del Instituto Barraquer de América, la Junta Directiva del Instituto.

Actuó como Presidente, el Doctor José I. Barraquer.

I: QUORUM. — Con el quórum estatutario el Presidente declaró abierta la sesión, procediéndose:

II: CONSTITUCION DEL TRIBUNAL DE HONOR. — La Junta Directiva del Instituto Barraquer de América, en cumplimiento de lo ordenado, se constituye en Tribunal de Honor, con el objeto de otorgar la primera Medalla Ignacio Barraquer y Barraquer.

El Tribunal de Honor, tras analizar las comunicaciones recibidas, de las Sociedades Oftalmológicas, Académicas de Medicina, Miembros de Honor del Instituto y ponderar cuidadosamente los méritos de todos y cada uno de los oftalmólogos propuestos para la distinción que se otorga, resuelve:

ARTICULO UNICO.

El Tribunal de Honor, en consideración de los logros científicos, labor humanitaria y en especial, por el desarrollo de la Crioextracción del Cristalino, unánimemente confiere la Medalla de Oro Ignacio Barraquer y Barraquer, al Profesor:

TADEUSZ KRWAWICZ

En constancia se firma la presente acta tal y como aparece:

El Presidente,
José I. Barraquer Moner

El Secretario,
Ignacio Barraquer Coll.

4—ENTREGA DE LA MEDALLA IGNACIO BARRAQUER Y BARRAQUER E INAUGURACION DEL PRIMUM FORUM OPHTHALMOLOGICUM POR EL EXCMO. SR. PRESIDENTE DE LA REPUBLICA DR. CARLOS LLERAS RESTREPO.

Señor presidente y miembros del Primum Forum Ophthalmologicum.

Señor profesor Krwawicz, señoras, señores:

No creo que los miembros de este Foro, que van a estudiar tan interesantes problemas de avance en la oftalmología, deban dar las gracias al Presidente de la República o al Gobierno Nacional de Colombia por participar en la inauguración de tan señalado evento científico. Yo creo que esas gracias deben ser dadas por mí y por el gobierno, a los organizadores del congreso y a los participantes. El hecho de que ellos hayan considerado que el gobierno colombiano y en particular el Presidente de la República, tendría o debía asociarse a un evento científico nos honra al gobierno y a mi grandemente.

Resulta también particularmente honroso, el que me haya correspondido hacer entrega de la primera Medalla establecida por el Instituto Barraquer de Colombia, para premiar los grandes avances científicos en el ramo de la ciencia, al cual ese Instituto se ha consagrado con un éxito innegable y que haya sido destinatario de este honor quien ya ha alcanzado en la ciencia contemporánea tan altos méritos por la introducción de una técnica científica nueva en la operación de la catarata, tema que precisamente será objeto de uno de los aspectos de los trabajos de este congreso. Quiero presentar, a nombre del gobierno, del pueblo colombiano y en mi propio nombre, un saludo cordial a los participantes en este foro científico, congratularme de que se reuna en esta ciudad de Bogotá, y desearles éxito en sus trabajos que sin duda vendrán a aumentar el caudal de conocimientos y el intercambio de experiencias que esta rama científica ha promovido con tanto éxito entre nosotros el doctor Barraquer.

PRIMUM FORUM OPHTHALMOLOGICUM

Por último, quisiera rendir un homenaje al nombre de Ignacio Barraquer y Barraquer.

Tuve el privilegio insigne de conocerlo personalmente hace algunos años en su clínica de Barcelona y de ver con cuánto espíritu científico y con cuánta mística trabajaba en el avance de la ciencia y reunía a su alrededor a un grupo de discípulos, muchos de los cuales han alcanzado ya una posición ilustre y destacada en diferentes países.

El hecho de que su hijo haya creado en Bogotá una clínica, hace honor al país y es para nosotros motivo de gran satisfacción. El nombre del doctor Ignacio Barraquer y Barraquer será recordado por los colombianos, no por esta creación, sino por la transmisión de conocimientos científicos y de experiencias a que ha dado lugar la fundación de la clínica y del Instituto Barraquer de América en Colombia. Y el numeroso grupo de colombianos que tuvo el privilegio de recibir los servicios y la atención del doctor Barraquer y de conocerlo, tendrá siempre en su memoria la imagen de este científico al mismo tiempo tan modesto y tan ilustre, dotado de tanto encanto personal y de tan seductora personalidad.

Renuevo a ustedes mis deseos por el éxito de este congreso y por una larga permanencia en esta capital de Colombia.

PRIMUM FORUM OPHTHALMOLOGICUM



Dr. Joaquin Barraquer
Dr. Derek Ainslie
Dr. José I. Barraquer
Dr. Derrick Vail

Dr. Tadeusz Krwawicz
Dr. Carlos Lleras Restrepo
Presidente de Colombia
Dr. H. Harms



Dr. Derek Ainslie
Dr. Derrick Vail
Dr. H. Harms

Dr. Carlos Lleras Restrepo
Presidente de Colombia
Dr. José I. Barraquer
Dr. Tadeusz Krwawicz

PRIMUM FORUM OPHTHALMOLOGICUM



Dr. H. Harms
Dr. Carlos Lleras Restrepo
Presidente de Colombia

Dr. José I. Barraquer
Dr. Tadeusz Krwawicz



Dr. H. Harms
Dr. Carlos Lleras Restrepo
Presidente de Colombia

Dr. José I. Barraquer
Dr. Tadeusz Krwawicz

SUTURES IN KERATOPLASTY AND CATARACT

By

**H. HARMS, M. D.
TÜBINGEN — ALEMANIA**

Mister President, Ladies and Gentlemen:

Refractive keratoplasty and cryoextraction of the lens are impossible without suturing the wounds of the eyeball. Suturing the wounds caused by accidents or by operations is an old but always important task in all surgery and therefore in ophthalmology too, which is the oldest daughter of general surgery. But suturing the wounds of the eyeball makes more difficulties than in other regions of the body. For a long time the dimensions of the surgical instruments and their bad quality were a great impediment for a correct suture of the walls of the eyeball. A special difficulty was the unequal properties of the different tissue of the eye. Every larger aperture of the eyeball consequently resulted in a higher risk. In this respect the cataract incision as performed by DAVIEL in 1750 was an extraordinary achievement.

The difficulties to close a wound of the eye in an accurate manner are subdued by the technical and surgical development of the past 40 years. I am not going to show you the numerous methods and techniques which marked the long way of this development. Many ideas side by side a lot of technical details would be tiring and in every case be uncomplete. I would like to report on this development mainly based on my personal experience. Of course this shows you only one side of the problem, but remember that I am one out of numerous ophthalmological surgeons who through years of work never had been satisfied with their operative results and who were continuously looking for an improvement of their techniques. Our present knowledge of wound closure in ophthalmology is a result of the above efforts.

The desire to close wounds of the cornea or sclera in keratoplasty and cataract surgery by direct sutures has been existing since 150 years. In

II. HARMIS

experimental keratoplasty in animals, the direct suture was used very early. In the human eye however direct suturing for closure of the wounds was used very seldom. I am sure, that it was tried more frequently, but because of the unsatisfactory results they were not reported.

Only a few decades ago it was only possible to close wounds in the cornea or at the border of the cornea directly. In keratoplasty this is clearly to be seen. Either the sutures are placed from limbus to limbus across the graft or the conjunctiva is stretched over the corneal graft and fixed at the opposite side by exact sutures. Instead of conjunctival tissue also other membranes, for instance egg membrane or thin rubber membrane are used for fixation of the graft.

Direct suturing of corneal incision was not common for a long time. However, a few authors stressed the importance of direct suture already very early, for instance CZERMAK in 1888, DE MENDOZA in 1889, KALT in 1895 and others. From the early thirties most surgeons were of the opinion that closure of the wound by a conjunctival suture or a covering with conjunctival tissue is necessary, especially after intracapsular cataract extraction. However, experienced surgeons (for instance ELSCHNIG in 1922) repeatedly pointed out that in corneal graft as well as after cataract extraction indirect closure of the wound is insufficient.

III. Now let us have a look on the pre-conditions which made the direct suture feasible since the last few decades.

a) **Instruments**

To close a wound in the eyeball by sutures we must have instruments to fix the border of the wound during suturing. We want to hold the margin cautiously and without additional traumatization but tight enough for the manoeuver with the needle. On one side because of the smallness of the eye we need fine instruments and on the other side because of the hardness of the wall, especially of the cornea, we need strong instruments. To combine both conditions was and is the problem of our instrument manufactures. Today we have better material, especially stainless steel and instruments machined more properly. So, during the last decades it became possible to develop a lot of delicate forceps and other instruments especially for surgery of the eye, which meet these conditions. They are all familiar to you so that I haven't to show them. Fortunately the manufacturers keep trying to improve the instruments in constant contact with the surgeons.

SUTURES IN KERATOPLASTY AND CATARACT

b) Needles

The most important instrument for suturing of cornea and sclera is the needle. I remember very well the difficulties we were confronted with in the midst of the thirties to put one of the smallest then available needles through the sclera or the cornea. Either the needle had a round cross section which resulted in a very high resistance in the tissue or it had a triangular cross section which led to damage the tissue. This was much improved when appropriate material was available for a more delicate and exact machining and when the manufacturers started to regard the needle as a cutting lancet shaped instrument and designed it accordingly. This development improved the wound treatment for the end of the thirties and during the war very much.

The development of suitable needle types is still going on. It extends on the different design of the anterior, middle and posterior parts and on the size of the needles. New operative techniques especially those of microsurgery stimulate the development.

c) Suture material

Simultaneous with the improvement of the needles were the intentions to improve the suture material. We have to distinguish between resorbable and not resorbable material. The surgeons have different opinions about the two types.

The advantage of resorbable material is that it is not necessary to remove the sutures and in some cases the irritation caused by the resorption of the material leads to a tighter scar. The compatibility of resorbable material varies, however. Sometimes irritating inflammations occur.

Usually resorbable material is a little thicker than not resorbable material. However, efforts are made to produce thinner threads. Figure shows below as examples: tendon of a rat tail, collagen 7/0 catgut 7/0 and 8/0 each with a simple knot.

Many surgeons prefer a not resorbable material because usually this is better tolerated. However, these threads have the disadvantage that they have to be removed.

Above in figure... you see not resorbable material: silk 7/0, beside of this the so-called Spanish silk, then follows a dark human hair and finally three nylon threads with 50, 40 and 30 micro diameter.

H. HARMS

Here I want to put in two little stories.

The human hair is that of a young female colleague who in the meantime —but not for this reason— became a professor of ophthalmology. For a lot of years she supplied us with her hair when we could not get Japanese hair. As we need a lot of suture material —malicious tongues call the Tübingen Eye Clinic “Harms sewing room”— all concerned were glad and satisfied when in 1960 we got the black nylon thread number 1 and no longer were forced to exhaust this source.

And the second story.

Looking for a new material, one of our colleagues met a patient of us who was a manufacturer of textiles. He recommended us a modern synthetic material which he used for the production of black mourning stockings. We got such stockings for a test, took single threads from the factory and so had found an extraordinary suture material which in the meantime is known all over the world as “Tübinger Faden”. So mourning may become joy.

Because of its excellent properties we stuck to this material. It combines flexibility with strength, is very thin, because of its black colour it is well visible and it is extraordinarily well tolerated. Neither cornea nor sclera nor iris show any reaction even after years.

The search for appropriate suture material is not finished all. In different parts of the world intense basis research is done concerning the properties and the suitability of new material.

d) **Operating microscope**

For exact suturing the surgeon must have good sight. During the last decades it has become matter of fact that intraocular operations are carried out at least with magnifying glasses. Since 1953 we use the Zeiss operating microscope. In the beginning it was applied in keratoplasty and in difficult operations in the anterior chamber. Since 1955 we use this microscope for all intraocular operations, especially in suturing it has become indispensable.

I am convinced that an exact suture, appropriate to the structure of the tissue can only satisfactorily be carried out under an operating microscope. The cornea has a thickness of about 1 mm. Often it is necessary to distinguish distances of 0,1 mm. so that exact closure of a wound is already a microsurgical act.

e) **Structure of sclera and cornea**

Apart from the mentioned conditions for optimal suturing of scleral and cornea the special properties of these two tissues are important. The sclera is a purely connective tissue, rather solid, a little elastic but composed out of fibres. This property you can observe when the tissue is wet or if you grasp it with an instrument. The densest layers are in the middle of the tissue, in the direction to the episclera but also in the other direction the layers are more loosely packed together. In contrary to the cornea the sclera is not having the two bordering compact membranes. Because of its structure, it is much easier to suture the sclera than the cornea. Tightening a knot you see that the scleral tissue is softer, more flexible and therefore is better workable than the corneal tissue.

The cornea too is composed in the greatest part of connective tissue with swelling properties which we can observe during all our operations. The parenchyma of the cornea is almost without any elastic elements. It lies between two solid membranes; the superior, a little thicker Bowman's membrane and on the lower side the Descemet's membrane. These two membranes are without any elasticity and rather stiff. They represent in some way the skeleton for the curvature of the cornea. The cornea offers a higher resistance to the piercing needle than the sclera. But we can suture this tissue without any damage since we are equipped with correctly formed, sharpened smallest needles.

V.

Now I am going to report something about my own experience in suturing corneal grafts.

My teacher Walter LOHLEIN in Berlin already in 1910 had dealt successfully with lamellar grafts in animal experiments and occasionally also in human eyes. Under the impression of the invention of FILATOV that cornea of a dead just died before is as good for a corneal graft as the cornea of living human beings, he continued his operations in 1935. From this time we have performed lamellar and perforating keratoplasties in a great number. In the beginning we fixed the graft indirectly by a so-called inverse conjunctival flap. This method was not satisfying because the graft was not fixed reliably enough in its proper position. The conjunctiva loses its stress and the threads cut through the tissue. Later we fixed thinnest rubber membranes with some tension circular at the limbal region, but these too lost their stress and therefore did not fix the graft enough in its position.

H. HARMS

The first experiments with direct suturing were started about 12 years later when we had got better needles. The settling turning point was brought by the operating microscope in 1953. It turned out that now because of the good vision control, it was possible to place direct sutures without danger for the posterior segments of the eye, although we did not dispose of as good needles and fine instruments as we have nowadays. To avoid the unpleasant complaints caused by the knots and ends of the single sutures we started at that time to fix the corneal graft by a running suture.

The technique we use in penetrating keratoplasty nowadays is the following:

When the graft is laid in the opening of the recipient's cornea it is fixed by four deep single sutures. The sutures must be laid exactly opposite of each other, so that finally a quadratic figure is seen on the surface of the graft by the stress of the thread. Then, we make the running suture with the single loops lying one near to the other. In doing so the needle is led from the center of the graft in a radial way towards the limbal region. The stitches are laid very deep through the corneal tissue. During this manoeuver the single sutures are usually removed. Finally, if the anterior chamber is restored by the injection of air or Ringer's solution, the single loops are cautiously pulled. Here, it is important to regard that no distortion of the corneal tissue results. The ends of the only knot are pulled into the corneal tissue and cut so, that the knot is buried under the epithelium and it is impossible that the patient has any trouble. The eye is quiet after a very short time.

A few days after the operation the dressing can be removed if the patient wears spectacles with a tight sealing on the side of the operated eye. But this condition is only achieved if the loops of the thread are tightened enough so that the epithelium can grow over the single loops. If some of them should be loosened a superficial vascularization may originate and they must be removed.

Usually we keep the suture for 2 to 3 months because the wound of the cornea is healing very slowly. It would be very fine, if it would not be necessary to remove the corneal suture. But usually this is necessary because the stress of the thread distorts the graft so that an irregular astigmatisme originates. We, however, try to avoid this unintended complication by applying the lowest necessary stress on the thread. It is difficult to aim at this because the tension of the running suture depends not only

SUTURES IN KERATOPLASTY AND CATARACT

from the pulling of the thread but also from the reactions of the recipient's cornea and of the graft. Swelling of the tissue may arise so that the final tension of the thread cannot be foreseen.

The thread is tolerated so well that it may be kept for months without any misgivings if only the loops are bedded under the epithelium. The removal of the suture is no technical problema: each second loop is cut by a Graefe knife and then we pull out the loop using the blunt side of the tip of the same knife. Now we can judge the final refraction and the improvement of the visual acuity. This means that the patient must have some patience for a few months.

The running suture was also introduced to avoid circular distortion of the graft during suturing. Even under the microscope it is rather difficult to make all stitches with a needle exactly in a symetrical way. If the single sutures are not lying exactly there where they are knotted, distortions must result which may influence the condition of the graft. A running suture with a lot of loops lying one beside the other fixes the graft very well so that it is not necessary to pull too much on the thread. Furthermore you may take care during each stitch that pulling at the thread does not cause any distortion on the tissue.

Some objections were made to our running suture. HALLERMANN said that the suture presses the outer margin of the wound more together so that the inner margins are gaping. But in my opinion this can only happen if the suture is placed too superficially. We prefer deep stitches which lie approximately in the posterior third of the corneal thickness. Careful controls of the inner border of the wound under the slit lamp showed us that HALLERMANN is not right. There is even more the danger that if the loops are strongly tightened, the inner borders of the wound are pressed together too much. In a few cases we made the running suture in the so-called meander shape which HALLERMANN has proposed but if the stitches are lying as deep as we are preferring the outer border of the wound tends to gape. Recently BARRIE JONES made some objections against our radial stitches. He thinks that it is better to pass the needle through the cornea in an oblique way to avoid a distortion of the graft. I think this can only happen if one relinquishes the four primary single sutures which fix the position of the graft and moreover pulls every loop in the running suture immediately after the performance of each stitch. However, if one starts with the running suture after having fixooted the graft by 4 single sutures, then removes step by step these sutures and stretches every loop in the described manner, the twisting of the graft is avoidable.

H. HARMS

One point of our suturing technique in keratoplasty is unsatisfying. Occasionally it happens, even 3 to 4 months after the operation, that if we remove the running suture the graft is not healed enough. Even, if this happens rather seldom and is easily repairable by some single sutures this is an unpleasant event. For this reason we are now looking for a technique by which the later removal of the thread is not necessary.

VI.

Now let's consider the influence of the suturing technique on our method of cataract extraction.

In the early thirties I had learnt to use in cataract surgery a corneal scleral incision with a conjunctival flap by means of a Graefe knife. This flap was fixed by some conjunctival sutures. But these sutures could not prevent anterior chamber hemorrhages or rupture of the wound with occasional prolapse of iris tissue. The bleeding into the anterior chamber, usually observed between the fourth and sixth day was a common event.

In 1953 I came to Tübingen to an Eye Clinic where for years the cataract extraction was performed with a pure corneal incision using a Graefe knife and without any suture. This technique showed in comparison to my former technique some advantages and disadvantages.

The advantages were:

that the operation was usually performed without any loss of blood,
that at every time one has a perfect survey on the operating field,
that late hemorrhages into the anterior chamber are very seldom,
and that the important and very delicate region of the anterior chamber angle is not touched.

Disadvantages were:

that the corneal wound often did not stick together,
that the anterior chamber was flat for a long time or even lost, which led to anterior synechiae and that the healing of the wound was very slowly.

Because of this comparison we decided to make as a routine technique a corneal incision but with a following suture of the wound. This was easily done under the operating microscope which had been available for us at that time. This is our technique until today. However, we are not making any more a Graefe incision because the direction is very oblique so that it is difficult to bring the two margins exactly together.

SUTURES IN KERATOPLASTY AND CATARACT

Nowadays we have the following technique:

Firstly we make a so-called two-step incision through the cornea using a piece of razor blade for the perpendicular incision of the superior circumference which goes approximately to the outer two third of the tissue. Then, the anterior chamber is opened by a pair of Vannas'scissors. After this, two corneal sutures are pre-placed through the deep layers of the tissue. The needle is introduced through the corneal margin where the tip of the needle should come through the angle between the two steps of the incision. The corresponding part on the scleral side of the corneal wound is looked for whilst the cornea is relaxed. Again the tip of the needle goes exactly through the angle of the two-step incision. Now, the knot is pre-placed and the thread is moved out of the wound. After the extraction of the lens the two pre-placed sutures are pulled and knotted 2 to 3 further sutures are laid, sometimes even more.

The peripheral iridectomy may be made either after opening of the anterior chamber or after the final closure of the wound. This may have some advantages in a few difficult situations.

In order to avoid that the knots of the single sutures give any complaints to the patient they are pulled into the canal of the stitch. This is very easy because the thread is so thin that even a five times twisted knot does have the diameter of the needle.

With our suturing technique in cataract extractions hemorrhages, ruptures of the wound and synechiae are extraordinarily seldom. In so far our expectations in this method came up completely. The corneal incisions heal very slowly because of the slow metabolism of this tissue. The threads are tolerated very well if the loop is imbedded under the epithelium. If not, just in the limbal region we soon see an irritation and a superficial vascularization. Therefore, every loosened loop which does not give anymore fixation to the tissue must be removed. But also the other correct lying threads must be removed months after the operation if the wound is healed. The reason is, that usually we have a higher astigmatism as long as the sutures are lying in the cornea. Immediately after the removal this refractive error is diminished or disappeared.

We already try during suturing to keep the astigmatism as small as possible. We do not pull more at the sutures as closure of the wound demands. But it is not possible to judge the extense of tension especially because the corneal tissue has a very different stiffness. In this point we are

H. HARMS

not satisfied with our present technique. Because our patients need preliminary spectacles which are exchanged two months after the operation when the sutures are removed. This shows that the corneal incision in cataract surgery confronts us with the same problem as the above mentioned in keratoplasty. The curvature of the cornea is altered by a lying suture.

Let us now consider how this is caused.

If we look at the corneal suture with high magnification so we can observe that small triangular distortions are visible just under the surface of the cornea which must be caused by the Bowman's membrane. These distortions are not altered even after months. The astigmatism of the cornea is also not changed very much during this time. This does not happen if the sutures lie in scleral tissue. Then a primarily existing astigmatism vanishes without recovering the threads during a more or less long time. These different properties are doubtlessly a consequence of the different structures of sclere and cornea. I mentioned above that the Bowman's membrane which is perforated by the single corneal stitch has no elasticity. Obviously, a pull at the membrane of Bowman causes the distortion of the curvature of the cornea. The parenchyma of the cornea itself is not stiff enough so that the stress results in a permanent astigmatism.

VII.

It follows from this that if the disadvantageous influence of the corneal suture on the refraction of the eye is caused by the stretch on Bowman's membrane, this membrane must not be touched. The suture should only be led through the soft perenchyma, that means it should be placed intracorneally.

The next figure shows an eye after cataract extraction in which in the upper nasal part 3 of the usual vertical sutures are placed whereas in the upper temporal part 2 loops lying horizontally to the surface are placed through the middle of the parenchyma, additionally a superficial horizontal tuture is placed. The intracorneal sutures only grasp loose corneal stroma. They close the wound. The reflexion of the corneal surface shows that a high astigmatism exists in the area of the vertical sutures, whereas in the region of the two horizontal sutures the astigmatism is only very small. But the photo with higher magnification reveals that in the region of these sutures the corneal wound has a superficial cleft. This is not surprising if we remember that the stroma of the cornea is rather soft which makes it impossible that a stronger pull joins the two margins of the wound in the

SUTURES IN KERATOPLASTY AND CATARACT

full thickness of the cornea. The deeply placed vertical suture closes as well the inner as the outer wound lips of the cornea; this leads to a perfect wound closure. Whereas the horizontal suture—at least if it is placed in the middle of the parenchyma—only brings into touch the inner wound lip and the parenchyma. For this reason we here need a second pulling action, leading also to an exact closure of the outer part of the wound.

This is an example out of a series of various new suturing techniques being investigated by us at present.

We are going to study the technique and the applicability of the intracorneal suture with the aim to avoid corneal refractive errors as consequence of our operating techniques. At the same time we hope being able to develop a technique releasing us from the later removal of the sutures.

Ladies and Gentlemen,

The last ideas should show that in no case all problems in corneal and scleral suturing are solved and that especially with regard to the refraction improvements are still necessary. In spite of this we can say that the direct suture of cornea and sclera is an important advance in ophtalmic surgery. The exact closure of the wound resulted in a higher security and better healing for our patients and avoids complications in the postoperative course.

The ophthalmological surgeons may nowadays place more extended wounds than before because they can control them by a careful suture. This gives us clear space of action for the development of new operating techniques.

CRYOEXTRACTION OF CATARACT AND ITS INFLUENCE ON THE DEVELOPMENT OF CRYO-OPHTHALMOLOGY*

By
TADEUSZ KRWAWICZ

The operative treatment of cataract is not always a simple task. Everyone who is practicing such operations is also familiar with their difficulties, which are often considerable. There are, of course, some universally accepted principles and more recent technical improvements which have created conditions for an easier and safer extraction of the cataractous lens. In spite of this, however, the risk of failure was still considerable, because the favourable result of the operations of total removal of cataract often depended on which was broken first: the delicate zonule fibres, or the sometimes even more delicate capsule of the opaque lens.

This commonly practiced, but difficult, and at the same time one of the most fascinating ophthalmological operations suffered from the great part that chance played in its performance. It must be said that this role of chance has been greatly diminished thanks to the most interesting variation of the technique of total extraction consisting in grasping the lens with a suction cup, instead with a forceps. This method has been spread by the work of Professor Ignacio Barraquer, who devoted a whole life of study and investigation to the problems of cataract surgery, and to whose memory I have the great honour to dedicate this lecture.

The endeavour to perfect the art of ocular surgery by all possible and available means has resulted during recent years in the utilization of cold as the basic physical principle of a surgical instrument. Based on the technology of extremely low temperatures, an new branch of surgery, and especially of ocular surgery, the so-called cryosurgery, has come into being¹.

* Ignacio Barraquer y Barraquer Memorial Lecture.

TADEUSZ KRZAWICZ

The idea to apply low temperature for cataract extraction presented itself during experimental investigations on the possibility of storing tissues by freezing. Some experiments with frozen-died animal lenses made it necessary to find a method of removing the lens undamaged from the eye. This proved rather difficult, as the lens was usually damaged. On that occasion a copper wire, soldered to a piece of metal refrigerated in a mixture of dry ice and alcohol, was used for the first time.

It was noticed that when the lens capsule was touched with the tip of the refrigerated instrument, for which we later suggested the name "cryoextractor", there occurred immediate, circumscribed freezing of the capsule, which attached itself to the instrument. In the course of further experimentation, a method of cataract extraction was developed.

The first reports^{2,3,4} on the possibility of applying low temperature for cataract extraction acted, to quote Bellows⁵, as a catalyst which stimulated a number of authors to undertake experimental and clinical investigations or further possibilities of the cryogenic technique, on new instruments and apparatus, and on the effects of cold on the ocular tissues. The ophthalmological world quickly realized the potentialities inherent in ocular cryogenics.

The history of cryoextraction is not so old as of most other ophthalmological operations. Only ten years elapsed since the moment when it was practiced for the first time¹. Nevertheless, this operation has found an almost universal acceptance and is regarded as the safest method of cataract extraction⁶.

In the first line, the application of low temperature established a basis for progress in the art of restoring sight to people affected with cataract. The uncertainty inherent in the traditional methods of cataract extraction can be removed by making use of low temperature. It can be said that the risk of capsular complications now belongs to the past and that we are not so far from ultimate stabilization in this field. In consequence, the operator's nervous tension is reduced⁷, and consistently good results can be assured. More and more ophthalmologists adopt the cryogenic technique because of its advantages over the application of the forceps or erisiphake⁸.

The tensile strength of the capsule grasped with the forceps is about 15 grams; for the erisiphake it is 17 or 18 grams, but it rises to 250 grams and more when the cryoextractor is used^{9,10}. The traction force is applied

CRYOEXTRACTION OF CATARACT

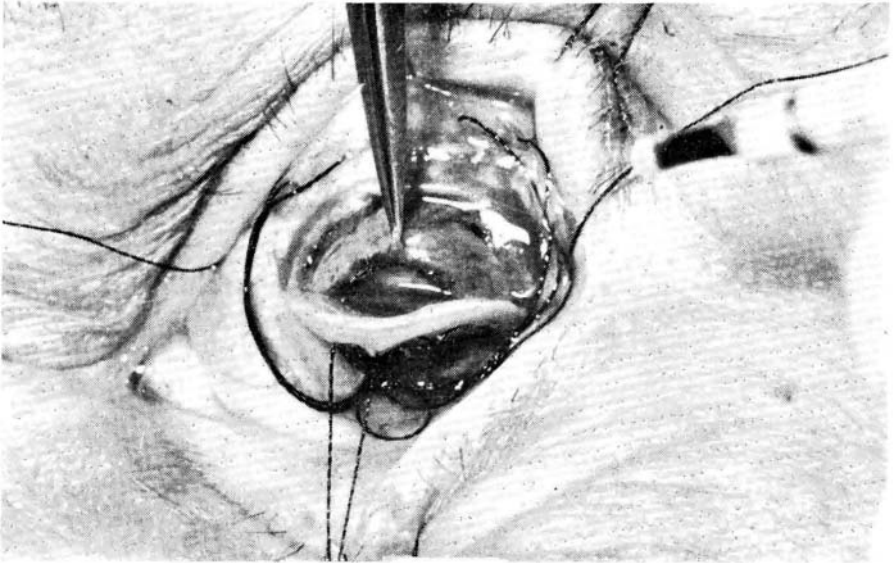


Fig. N° 1

The corneal flap is lifted and is held in this position by the auxiliary suture. The forceps grasps the iris, and the cryoextractor is ready for use.

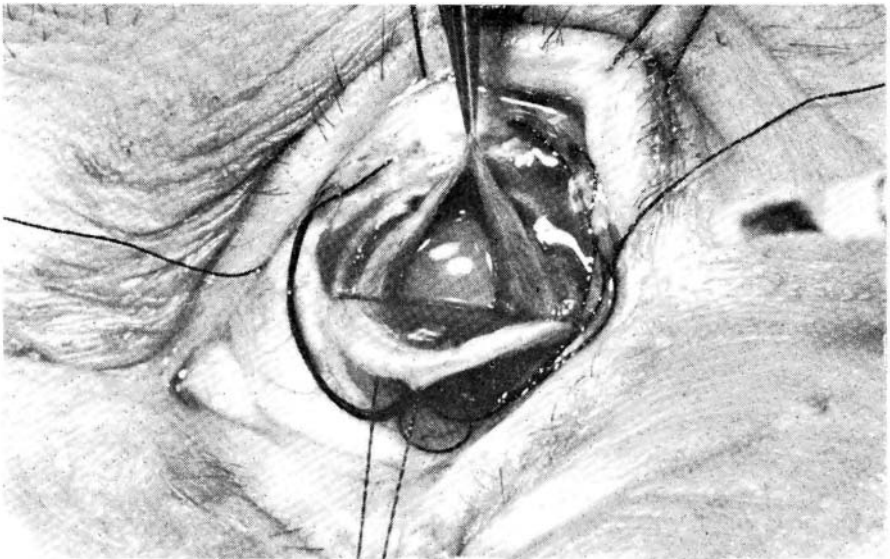

Fig. N° 2

The iris is lifted with the forceps in the form of a tent.

to the capsule over a large area; thanks to this circumstance there is no need to use counterpressure, so that the risk of vitreous loss is reduced¹¹.

The result of the operation does not depend on the type of the cryoextractor, but on the condition of the cataract and on the operator's experience¹². Cryoextractor does not require any changes in the operative technique; every operator may safely go on using his preferred technique.

Cryoextraction has brought about a real progress, evidenced by better operative results and by a decreased incidence of complications¹³. In comparison with other methods, it assures the best results as far as visual acuity is concerned^{14,15,16,17,18}. The occurrence of complications depends on the experience of the operator, and those who apply cryoextraction¹⁹ agree in the opinion that all types of cataract can be removed intracapsularly and with greater security than by any other method.

In the original method of cryoextraction of cataract^{2,3,4}, the initial stages of the operation do not differ much from those of the conventional methods, up to the moment when the cataract is exposed. It is then that the ball-shaped end of the cryoextractor is applied to the lens. Immediately upon application, the refrigerated part of the capsule adheres firmly to the instrument, so that the lens can be manipulated freely.

We are now convinced that cryoextraction is a method that spares the ocular tissues by enabling the surgeon to operate more delicately. We have also arrived at the conclusion that this operative procedure can be simplified even more than it could be initially expected. No winder section is now necessary, or counterpressure, or retraction of the iris with a special instrument; there is also no need of the operative assistance being engaged more than with the traditional methods¹.

The classical method of cryoextraction, which we employed for several years, required a very active co-operation of the operative assistance. The assistant lifted the corneal flap and retracted the iris with a retractor or another instrument, and thus bore a great part of the responsibility for the outcome of the operation. This circumstance sometimes gave rise to complaints that a well-trained and highly qualified assistance is not always available. Besides, there are operators who prefer to be independent of extraneous help¹. The need of a competent assistant was considered as a drawback of cryoextraction²⁰, and our personal opinion was not much different.